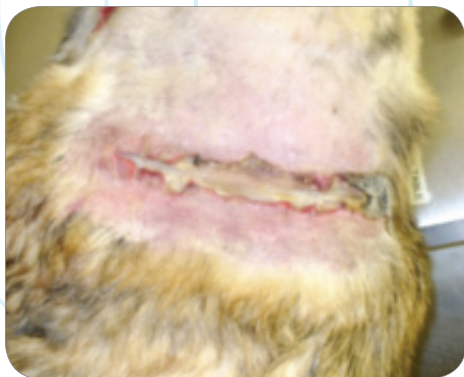

# CASE STUDY

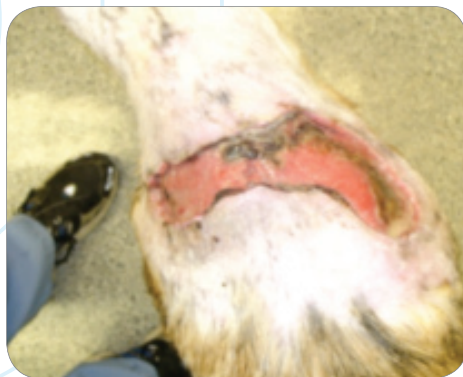## Soft Tissue Trauma

**K-LASER**<sup>™</sup>  
USA

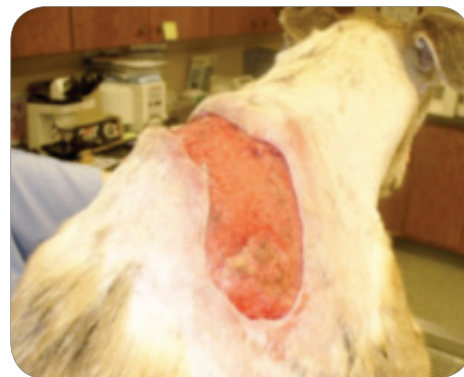1106 Harpeth Industrial Court  
Franklin, TN 37064  
866-595-7749 (v) • 615-261-3535 (f)  
[www.k-laserusa.com](http://www.k-laserusa.com)



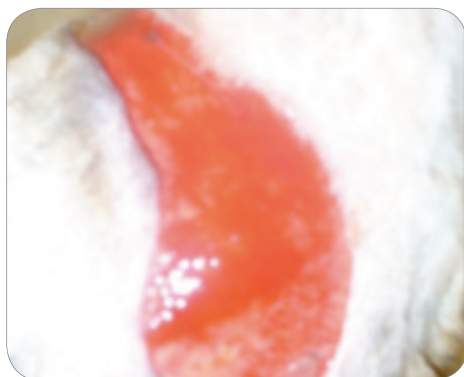MARCH 14



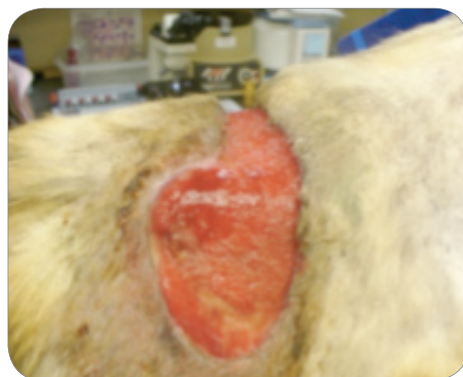
MARCH 18



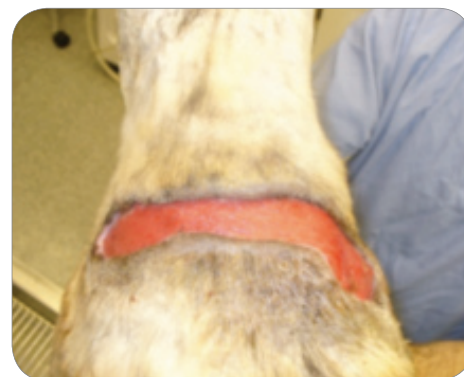MARCH 22



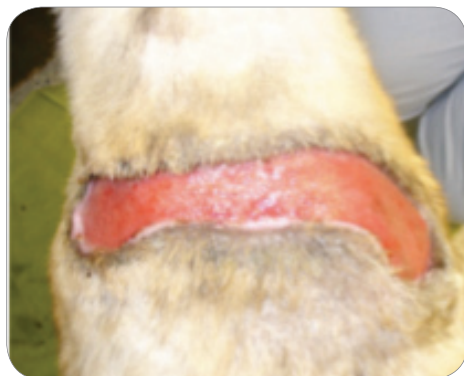MARCH 28



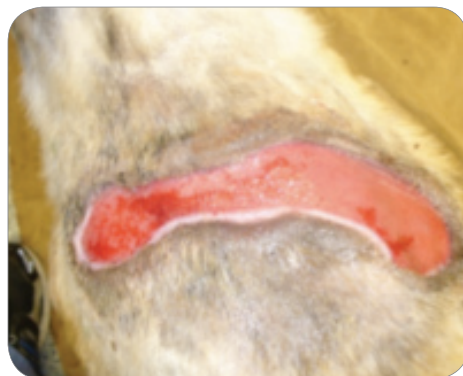APRIL 4



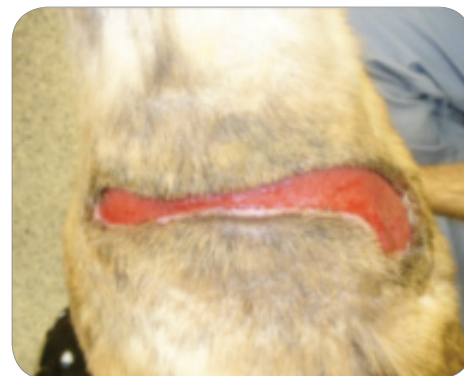APRIL 12



APRIL 23



APRIL 26



APRIL 30



### **Tucker, Greyhound**

Presented March 10, 2010. Dog attack with extensive injuries

**LOCATION:** Back

**DEVICE:** K-Laser 6d

**PROTOCOL:** Soft Tissue Trauma

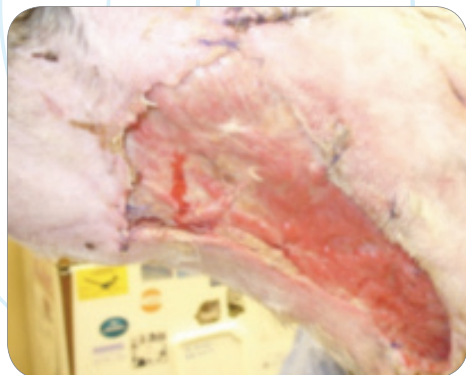
CASE AND PHOTOS COURTESY OF CALVIN CLEMENTS, DVM, CCRP KYLE KOLVA, CVT, CCRP AT PALMYRA ANIMAL HOSPITAL, PALMYRA, PA

# CASE STUDY

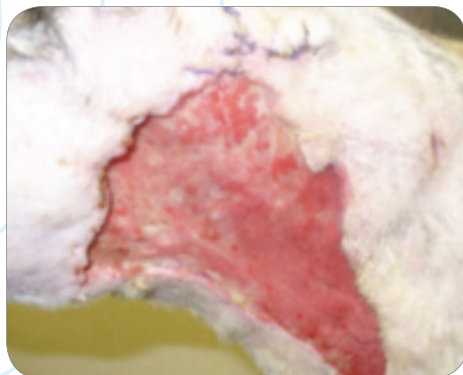
## Soft Tissue Trauma

**K-LASER**<sup>™</sup><sub>USA</sub>

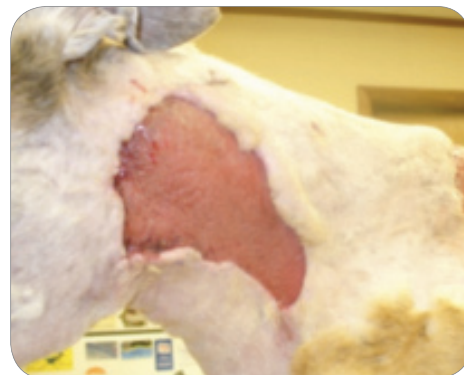1106 Harpeth Industrial Court  
Franklin, TN 37064  
866-595-7749 (v) • 615-261-3535 (f)  
[www.k-laserusa.com](http://www.k-laserusa.com)



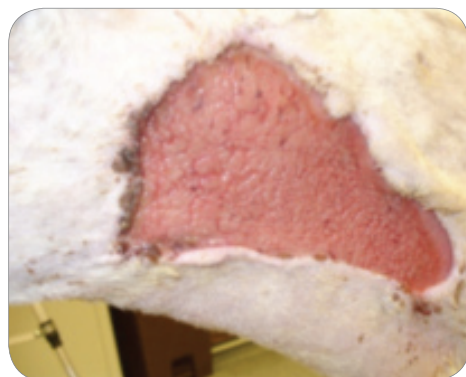
MARCH 10



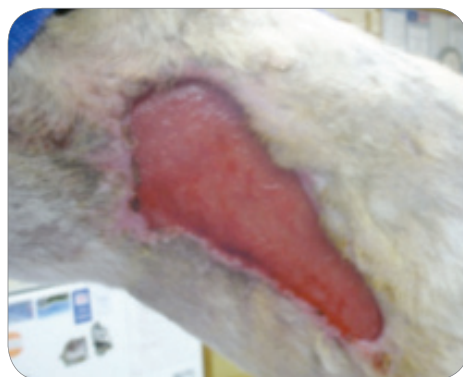MARCH 14



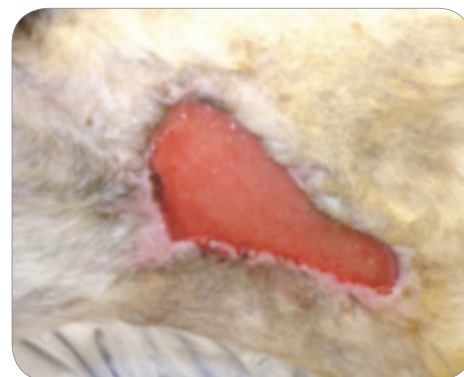
MARCH 22



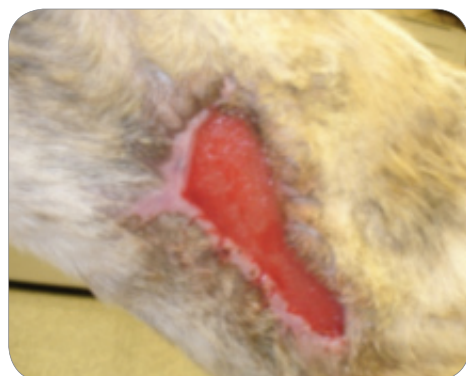
MARCH 24



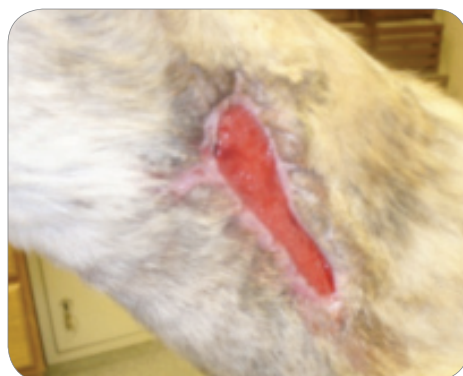APRIL 4



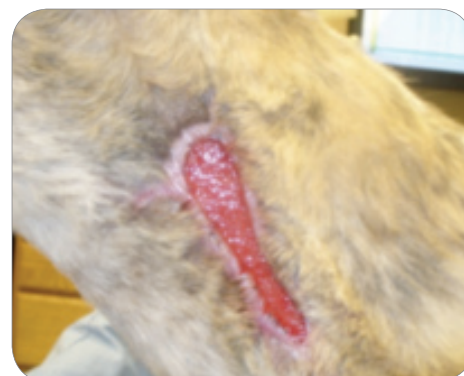APRIL 12



APRIL 18



APRIL 26



APRIL 30



### **Tucker, Greyhound**

Presented March 10, 2010. Dog attack with extensive injuries

**LOCATION:** Neck, Left Side

**DEVICE:** K-Laser 6d

**PROTOCOL:** Soft Tissue Trauma

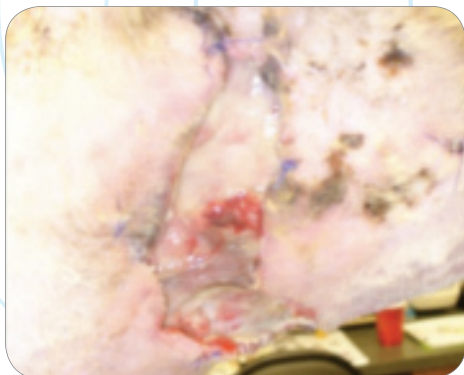CASE AND PHOTOS COURTESY OF CALVIN CLEMENTS, DVM, CCRP KYLE KOLVA, CVT, CCRP OF PALMYRA ANIMAL HOSPITAL, PALMYRA, PA

# CASE STUDY

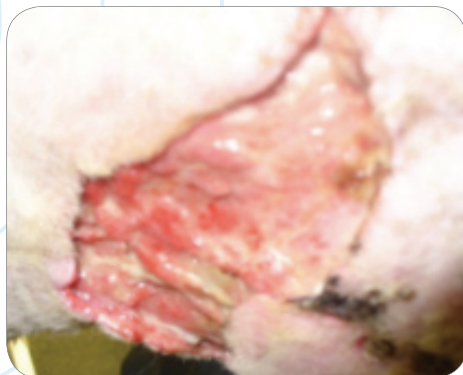
## Soft Tissue Trauma

**K-LASER**<sup>™</sup>  
USA

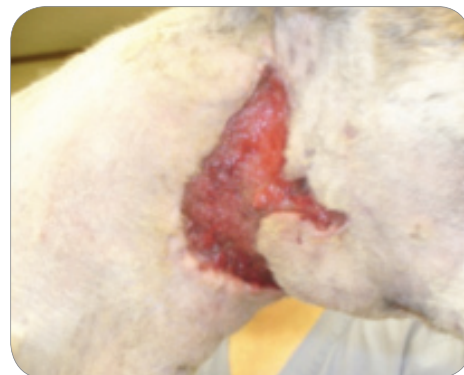1106 Harpeth Industrial Court  
Franklin, TN 37064  
866-595-7749 (v) • 615-261-3535 (f)  
[www.k-laserusa.com](http://www.k-laserusa.com)



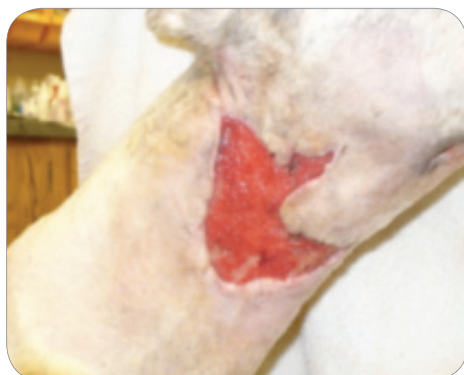MARCH 10



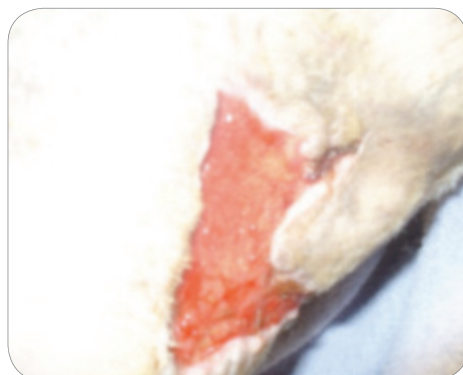
MARCH 14



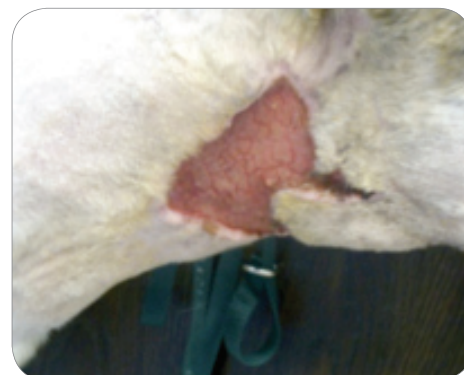MARCH 22



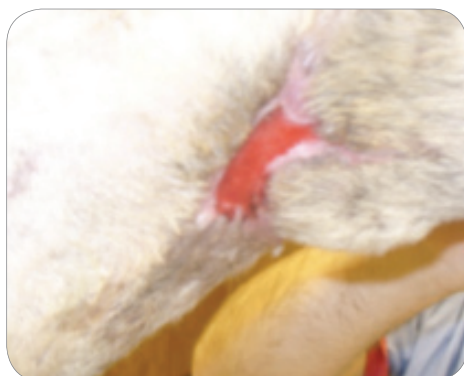MARCH 24



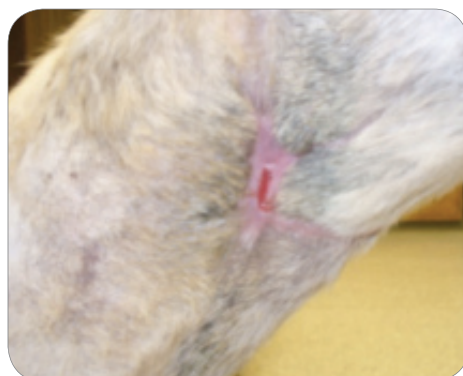MARCH 29



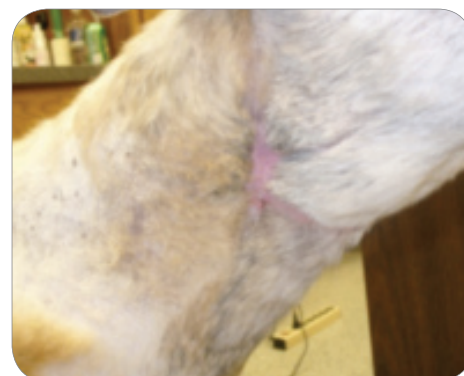APRIL 5



APRIL 12



APRIL 23



APRIL 26



### **Tucker, Greyhound**

Presented March 10, 2010. Dog attack with extensive injuries

**LOCATION:** Neck, Right Side

**DEVICE:** K-Laser 6d

**PROTOCOL:** Soft Tissue Trauma

CASE AND PHOTOS COURTESY OF CALVIN CLEMENTS, DVM, CCRP KYLE KOLVA, CVT, CCRP OF PALMYRA ANIMAL HOSPITAL, PALMYRA, PA